

Clinical Experience in the Use of Free and Pedicled Radial Forearm Flap in Reconstruction of Major Head and Neck Defects

HOSSAM Y. ELKAFRAWI, M.D. and ABDELMOHSEN K. ABOUELDAHAB, M.D.

The Department of Plastic Surgery, Faculty of Medicine, Alexandria University

ABSTRACT

Since its introduction in by Yang et al., the radial forearm flap has become the flap of choice in head and neck reconstruction, because it is reliable, versatile, and yields a long pedicle and a thin supple skin paddle.

In our department, and even with our limited resources, the free radial forearm flap has grown to be the workhorse for reconstruction of major defects in the head and neck. This has encouraged us to strain it a little more and use it as a pedicled variant in few selected cases in whom the free flap variant would have posed some problems.

This paper is to comment on our experience with 16 free radial forearm flaps, as well as 3 pedicled flaps with were used to successfully reconstruct large head and neck defects.

INTRODUCTION

The aetiology of major head and neck defects is quite variable, and will subsequently result in variably composed defects, reconstruction of such defects requires transposition of thin, pliable, and, preferably, sensate soft tissues, those defects also may require the incorporation of other structures such as bone or tendons. A long vascular pedicle is also desirable because the vessels used for the anastomosis are usually found in the neck, hence the decision about which flap to use for head and neck reconstruction is based on the defect size, the type and amount of missing tissue, necessary pedicle length, and requirements for reinnervation, as well as the surgeon own preference according his experience.

The radial forearm free flap (RFFF) was developed in China 1978 and described in Yang's 1981 article [1]. It was then popularized in the west, especially by Song and Muhlbauer 1982 [2,3].

Over the years the radial forearm free flap has grown to become the workhorse of reconstructive surgery in head and neck especially for defects following tumor extirpation, those defects usually involves loss of the thin mucosal lining of the oral cavity, pharynx, or larynx together with loss of the overlying facial muscles and skin.

The RFFF was a major breakthrough in reconstructive surgery, due to various facts; first, its vascularisation is axial providing a rich anastomotic network which supplies septocutaneous perforators to the skin all along the flap [4] as well as muscular and periosteal branches, so vascularised bone segment, tendons (Flexor Carpi Radialis and Palmaris Longus) and nerves (the lateral and medial antebrachial cutaneous nerves) can be raised with the flap [4]. Second, its rich venous network provided by the combination of both superficial and deep venous network allows harvesting very large skin padel, without the fear of developing peripheral venous congestion. Furthermore harvesting of the RFFF is usually easy and uncomplicated due to large vessels, and predictable anatomy, may be performed simultaneously by a second surgical team thereby reducing the overall time for surgery, Last but not least the long vascular pedicle; the double superficial and deep venous networks allow many microsurgical options [4].

All of this allows for the reconstruction of a large complex defect like those we are usually met with following tumour extirpation.

Meticulous vessel preparation, gentle handling, correct positioning of the vessels and careful anastomosis technique all reduce the incidence of failure [5].

MATERIAL AND METHODS

This paper included nineteen patients who were admitted to the plastic surgery service in the Alexandria Main University Hospital in the period between 2004 and 2010, fourteen male patients and five females were managed in this study by a radial forearm flap to reconstruct a major defect in the head and neck area. The age of our patients ranged between 22 and 70 years. The aetiology of those defects was recurrent skin tumours, road traffic accidents and gunshots. The size of the

defect that needed reconstruction ranged between 8 X 10cm to 11 X 17cm.

All patients were subjected to:

- Full history taking, clinical examination (local and general) routine laboratory investigations.
- Medical imaging studies including:
 - a- Plain X-ray for the forearm A-P (antero-posterior) and lateral views.
 - b- Head and neck CT scanning for cases with oncological aetiology.
 - c- Doppler flowmetry for the forearm to assess the condition of radial and ulnar arteries.

Surgical technique:

Two teams approach was utilized in all oncological cases, and a single team approach for non oncological cases. The RFF was raised according to the classical technique starting from distal forearm to proximal, the superficial radial nerve was sacrificed, the superficial venous system was preserved and in most cases the cephalic vein was traced till the cubital fossa and its connection to the deep system preserved and the vein used for the venous anastomosis (Fig. 1).

A suitable recipient artery was usually chosen from the branches of the external carotid in the neck or even the external carotid itself, the internal jugular vein was the preferred site for venous anastomosis in almost all cases of FRFF (Fig. 2).

In pedicled cases the flap was raised in the same manner of its free counterpart, and the flap was completely islandised on its vascular pedicle, a narrow strip of skin was retained over the proximal part of the neurovascular bundle, and a small piece of SSG applied to cover its undersurface (Fig. 3). Flap pedicles were divided at bedside, three weeks later, after temporary test-clamping of the pedicle, and flap insetted 3-5 days later under local analgesia.

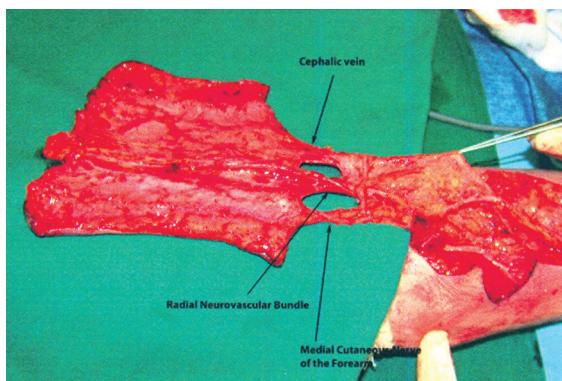


Fig. (1): The cephalic vein was traced till the cubital fossa and its connection to the deep system preserved and the vein used for the venous anastomosis.

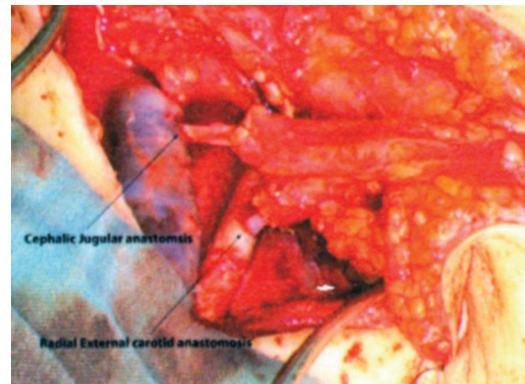


Fig. (2): The internal jugular vein was the preferred site for venous anastomosis in almost all cases of FRFF.

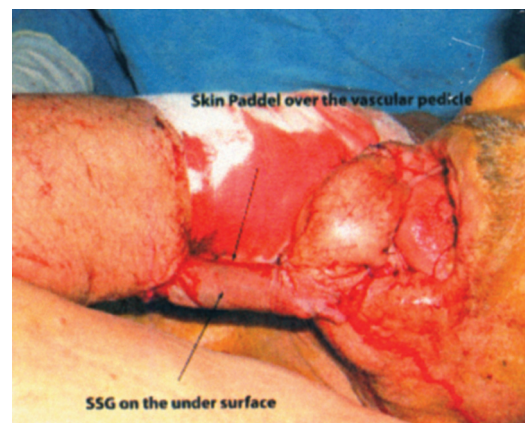

Fig. (3): The flap was completely islandised on its vascular pedicle, a narrow strip of skin was retained over the proximal part of the neurovascular bundle, and a small piece of SSG applied to cover its undersurface.

RESULTS

A- Free radial forearm flaps were used successfully to manage 16 patients with major head and neck defects in our department in the period from July 2004 and January 2010 with a follow-up period ranging between 3 years and 6 months. Our youngest patient was 22 years while our eldest patient was 64 years old, with an average of 46 ± 12.91 , out of these 11 were males while 5 were females.

The flaps used to cover the defect ranged in dimensions between 8 X 11cm to 10 X 17cm with sizes ranging between 88 cm² and 170cm² with an average of 122.56 ± 37.75 .

Recurrent skin tumours was the most common aetiological factor in our study and represented 11 cases out of 16 followed by trauma in 4 cases while extensive vascular malformation was the cause in one patient. The commonest site for reconstruction was the cheek in 6 cases (Case 1 Figs. 4-8), lower

lip in 5 cases (Case II Figs. 9-12), upper lip in 3 cases and forehead in 2 cases. In 13 of our patients the reconstruction needed included both mucosal lining and skin coverage.

All flaps survived completely, however, we had 3 cases of flap congestion detected in the early post operative period, they were all in cases where the recipient vein was not the internal jugular, and they were all salvaged by immediate readmission to the operating theater and revising the venous anastomosis, in two of them this meant a new anastomosis to the internal jugular. Donor site morbidity in the form of partial loss of the skin graft applied to the forearm was our most common complication, met with in cases, it was managed conservatively by proper dressing, however, it required regrafting in two cases. Haematoma was our second most common complication met with in 4 cases, 2 of them was in between the two layers of the flap, where it was used to give both lining and coverage to oral defects, and 2 was in the neck at the site of vascular anastomosis, in cases the patient was taken back to the operating theater and the cause dealt with.

Partial flap dehiscence and temporary fistulae were seen in 4 cases. Fistulae closed by dressing while secondary sutures were required to manage wound dehiscence.

B- We had three cases of pedicled radial forearm flap group, all were males, their ages were 64, 62, and 70 years and the largest flap was 17X15cm with an average size of 147.3 ± 94.4 .

Two of our cases were used to treat recurrent skin tumours of the head and neck, while the third case was to manage a firearm injury, in one case the patient had a central scalp defect (Case IV, Figs. 17-21), and the second was a full thickness cheek defect while the third was a full thickness lower lip defect.

All cases survived completely, however we partial wound dehiscence in one case that was managed by secondary suture. Partial skin graft loss that responded to dressing in another case.

But the most disturbing drawback that was seen in all three cases was shoulder and elbow stiffness, however, they responded well to three months of postoperative physiotherapy.

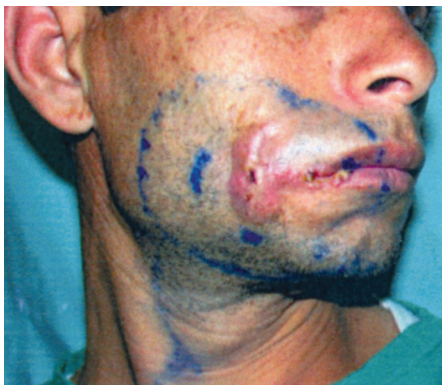

Fig. (4): Case I, Marking.

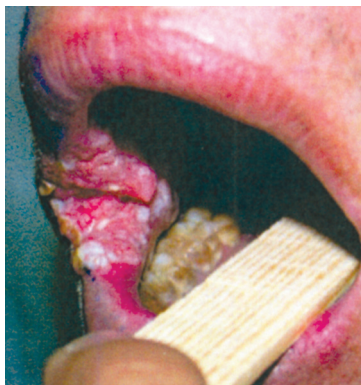


Fig. (5): Case I, Lesion.

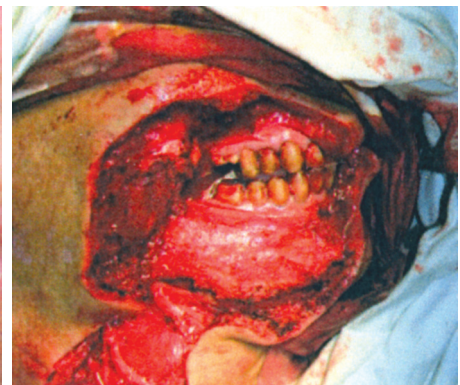


Fig. (6): Case I, Excision.

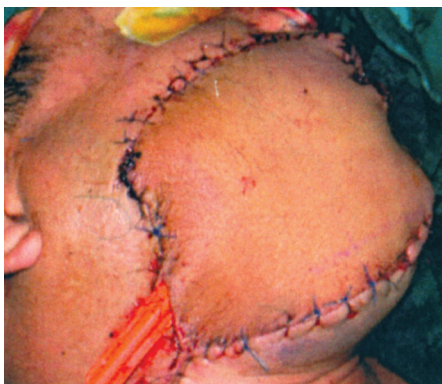

Fig. (7): Case I, flap in place.

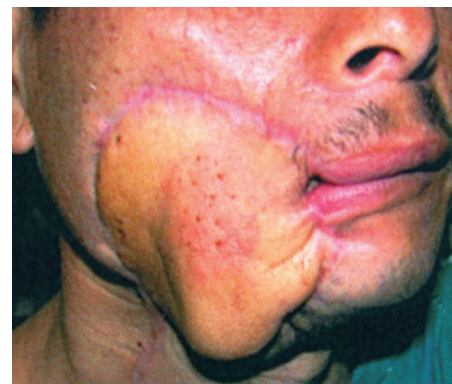

Fig. (8): Case I, late post-operative.

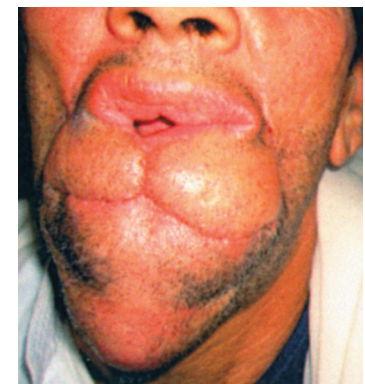

Fig. (9): Case II Lesion.

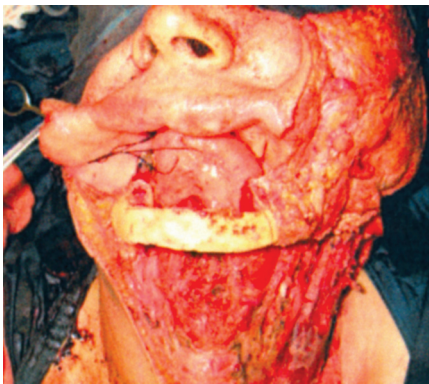

Fig. (10): Case II Excision.

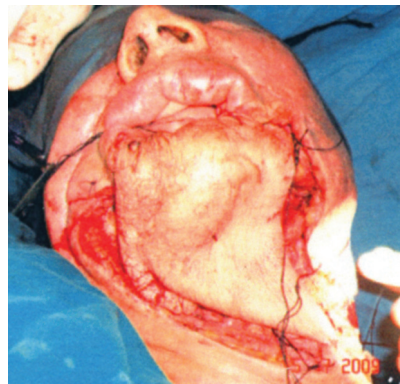


Fig. (11): Case II flap in place.

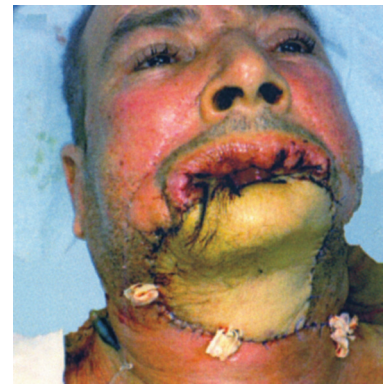

Fig. (12): Case II Post-operative.

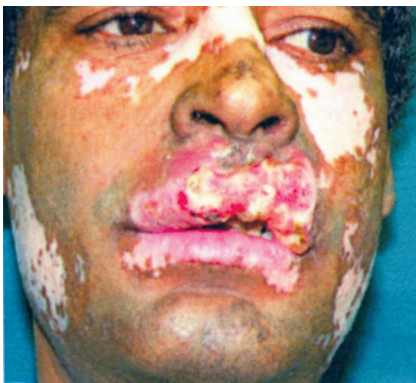

Fig. (13): Case III Lesion.

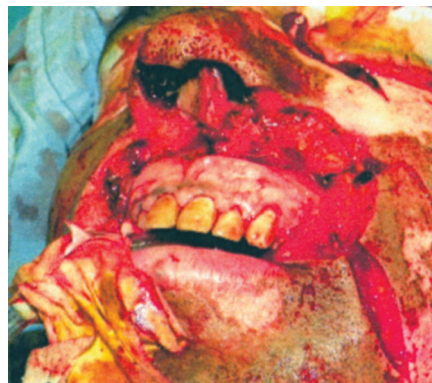

Fig. (14): Case III Excision.

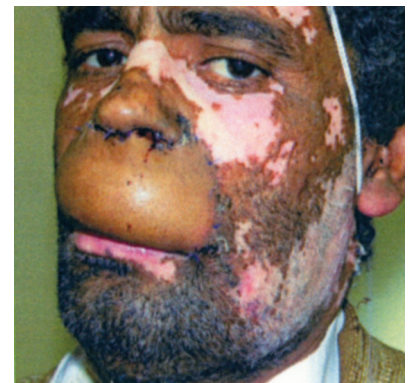

Fig. (15): Case III late post-operative.

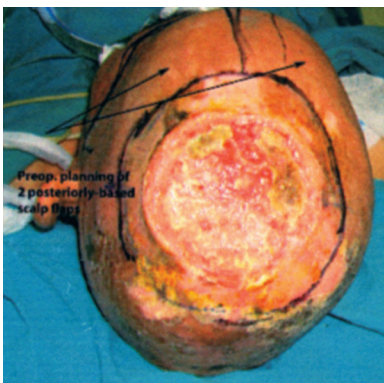


Fig. (16): Case IV Lesion.

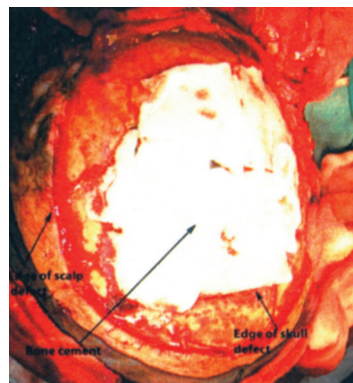


Fig. (17): Case IV Excision.

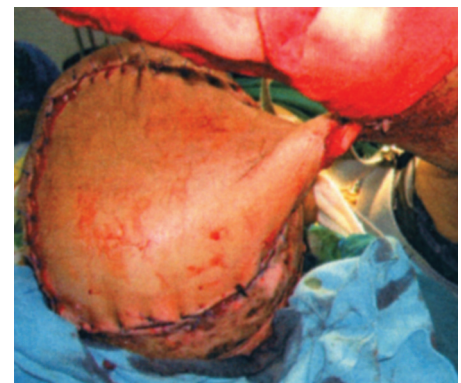


Fig. (18): Case IV flap in place.

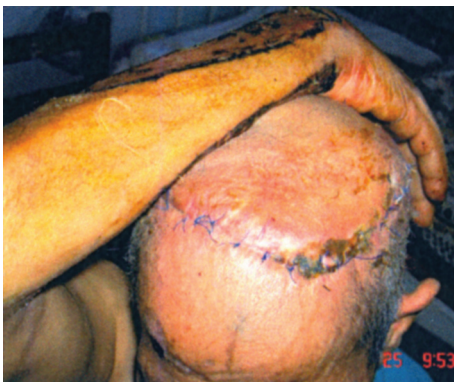

Fig. (19): Case IV post-operative.

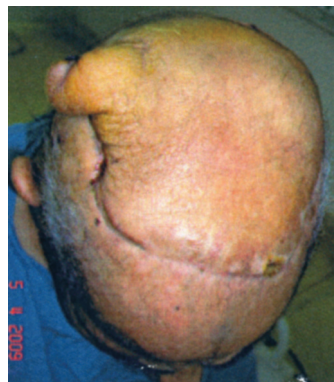

Fig. (20): Case IV after separation.

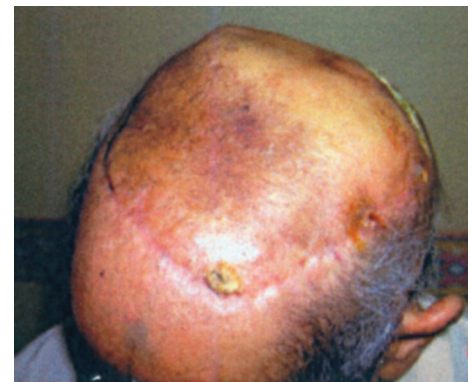

Fig. (21): Case IV after separation.

DISCUSSION

A radial forearm free flap is a versatile fascio-cutaneous flap first described by Yang et al. [1] and Song et al. [2] from China in 1982, who used it to treat burn contracture. Therefore, the flap is also known as the "Chinese" flap. Soutar et al., in 1983 popularized this flap for head and neck reconstruction and has been applied extensively by others since then [6,7], high success rate has been described by so many authors that the flap has become the golden standard in head and neck reconstruction. Hence our experience with this flap comes in accordance to the public concepts.

Khashaba and McGregor [8] demonstrated equal and adequate flow through the superficial and the deep system of veins by occluding one or the other system, in situ, during flap harvest.

Valanteno et al., showed that the communicating vein between the superficial and deep system is present in 95% of hands examined and described increased reliability rate in large flaps when using the cephalic vein for venous anastomosis after including the communicating vein thus combining the deep and superficial system in the same time. In our work we resorted to the same technique to insure flap reliability especially in our larger flaps, which proven useful since we did not have any cases of peripheral congestion inspite of the large size of the flaps used in most cases. Venous problems were minimized later in our work by performing the venous anastomosis to the internal jugular vein which reduces the chances of venous occlusion to minimum.

Our success with the free RFF has encouraged us to apply the same principle to raise and harvest very large pedicled island RFF that were used to cover the defects in patient whom are considered unsuitable to undergo microvascular procedures. Our work proves this technique to be useful and suitable to provide adequate coverage for major head and neck defects in such patients.

REFERENCES

- 1- Yang G.F., Chen P.J., Gao Y.Z., et al.: Forearm free skin flap transplantation: A report of 56 cases. 1981. Br. J. Plast. Surg., 50: 162-5, 1997.
- 2- Song R., Gao Y., Song Y., et al.: The forearm flap. Clin. Plast. Surg., 9: 21-6, 1982.
- 3- Muhlbauer W., Herndl E. and Stock W.: The forearm flaps. Plast. Reconstr. Surg., 70: 336-44, 1982.
- 4- Bricout N., Chretien B., Servant J.M., et al.: The Chinese forearm flap, or continuous axial vascular pedicle flap. Ann. Chir. Plast. Esthet., 31: 119-28, 1986.
- 5- Mark J., Alan T. and Willian P.: Double venous anastomosis for the radial artery forearm flap. Improving success and minimizing morbidity. Journal of Cranio-Maxillofacial Surgery, 37: 253-257, 2009.
- 6- Soutar D.S., Scheker L.R., Tanner N.S.B. and McGregor I.A.: The radial forearm flap: A versatile method for intraoral reconstruction. Br. J. Plast. Surg., 36: 1, 1983.
- 7- Soutar D.S. and McGregor I.A.: The radial forearm flap in intraoral reconstruction: The experience of 60 consecutive cases. Plast. Reconstr. Surg., 78: 1, 1986.
- 8- Khashaba A.A., McGregor I.A.: Haemodynamics of the radial forearm flap. Br. J. Plast. Surg., 39: 441-450, 1986.